

# Ureteral avulsion caused by through and through turniti

*by Syakri Syahrir*

---

**Submission date:** 31-Jul-2022 08:03PM (UTC-0400)

**Submission ID:** 1877382179

**File name:** Ureteral\_avulsion\_caused\_by\_through\_and\_through.pdf (1.14M)

**Word count:** 1731

**Character count:** 9577

3  
Available online at [www.sciencedirect.com](http://www.sciencedirect.com)

ScienceDirect

journal homepage: [www.elsevier.com/locate/radcr](http://www.elsevier.com/locate/radcr)

## Case Report

# Ureteral avulsion caused by through and through penetrating injury of the pelvis ☆☆☆

Syakri Syahrir<sup>a,\*</sup>, Khoirul Kholis<sup>a</sup>, Muhammad Asykar Palinrunji<sup>a</sup>, Syarif<sup>a</sup>, Abdul Azis<sup>a</sup>, Andi Zulfatulsyah<sup>b</sup>, Muhammad Faruk<sup>b</sup><sup>a</sup> Division of urology, Department of surgery, Faculty of Medicine, Hasanuddin University, Indonesia<sup>b</sup> Department of Surgery, Faculty of Medicine, Hasanuddin University, Makassar, Indonesia

## ARTICLE INFO

## Article history:

Received 22 March 2022

Revised 4 April 2022

Accepted 5 April 2022

Available online 5 May 2022

## Keywords:

Ureteral avulsion

Ureteral injury

Penetrating injury

Ureteral stent

## ABSTRACT

Ureteral avulsion is one of the rare cases in urology considering that this structure is well-protected in retroperitoneal location. However, the presence of penetrating pelvis injury should raise high clinical suspicion that ureteral avulsion may present in this case. We report the case of ureteral avulsion in patients caused by through and through penetrating injury of the pelvis. We managed ureteral avulsion by performing end-to-end anastomosis along with ureteral stenting. A multidisciplinary approach was performed to treat other structural damages. Finally, after two months, ureteral stent was removed and ileal-re-anastomosis was performed.

© 2022 The Authors. Published by Elsevier Inc. on behalf of University of Washington.

This is an open access article under the CC BY-NC-ND license

[\(http://creativecommons.org/licenses/by-nc-nd/4.0/\)](http://creativecommons.org/licenses/by-nc-nd/4.0/)

## Introduction

Trauma is the leading cause of death in individuals of productive age, particularly in the age range of 1 year to 44 years. Enterourinary trauma accounts for about 10% of all trauma cases. Moreover, ureteral trauma is rare, accounting for only about 1% of all urologic trauma cases. The most common cause was iatrogenic trauma (75%), followed by blunt trauma (18%), and sharp force trauma (7%). One

kind of sharp trauma that can cause injury to the genitourinary is penetrating trauma. Most penetrating trauma is caused by gunshot wounds or stab wounds. Penetrating trauma generally requires exploratory surgical management [1–3].

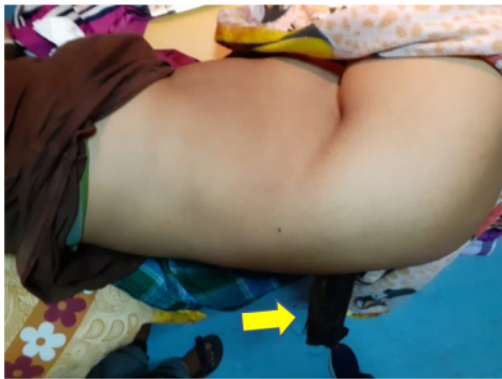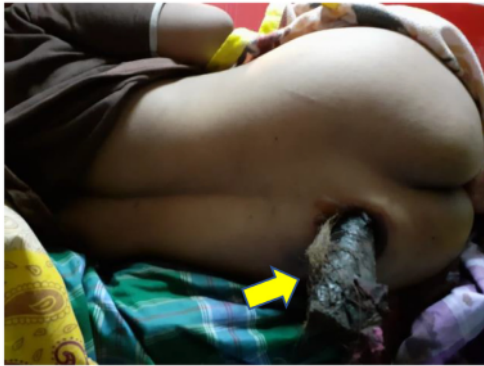Lower genitourinary tract trauma can be life threatening and have a significant impact on quality of life [1]. Prompt diagnosis and appropriate management are essential in limiting mortality and morbidity. Here, we report a case of penetrating trauma and ureteral rupture.

\* Funding: This research did not receive any specific grant from funding agencies in the public, commercial, or not-for-profit sectors.

\*\* Competing Interests: The authors have no competing interest to report.

\* Corresponding author: Syakri Syahrir. Division of urology, Department of surgery, Faculty of Medicine, Hasanuddin University, Makassar, Indonesia. Jalan Perintis Kemerdekaan KM 11, Makassar, 90245, Indonesia.

E-mail addresses: [drsyakrisyahrir@gmail.com](mailto:drsyakrisyahrir@gmail.com) (S. Syahrir), [khoirulkholis@yahoo.com](mailto:khoirulkholis@yahoo.com) (K. Kholis), [apalinrunji@yahoo.com](mailto:apalinrunji@yahoo.com) (M.A. Palinrunji), [syarifbakri@hotmail.com](mailto:syarifbakri@hotmail.com) (Syarif), [abdul.azis031@gmail.com](mailto:abdul.azis031@gmail.com) (A. Azis), [andizulfatulsyah@gmail.com](mailto:andizulfatulsyah@gmail.com) (A. Zulfatulsyah), [farox8283@gmail.com](mailto:farox8283@gmail.com) (M. Faruk).<https://doi.org/10.1016/j.radcr.2022.04.006>1930-0433/© 2022 The Authors. Published by Elsevier Inc. on behalf of University of Washington. This is an open access article under the CC BY-NC-ND license (<http://creativecommons.org/licenses/by-nc-nd/4.0/>)



**Fig. 1 – A clinical photo of patients showing an iron penetrating from left buttocks to the left inguinal (arrow).**

### Case report

A 37-year-old woman was transferred to our emergency department from secondary hospital following penetrating pelvic injury. The patient is a housewife who was cooking at home. She was cooking using liquefied petroleum gas stove, when suddenly, the liquefied petroleum gas stove exploded. The patient saw an iron object thrown by the explosion toward her then penetrated her pelvic from the left buttocks to the left inguinal (Fig. 1). She complained pain from the lower left abdomen to the back since 12 hours ago. Her initial vital signs were hypotensive (90/35 mm Hg) and tachycardic. We noticed an open wound with the size of 8 × 6 cm with irregular and black edges, necrotic and bone based. She had not been taking any drugs. Laboratory examination results were normal, except for an increased a white blood count of  $23.6 \times 10^3/\mu\text{L}$  (normal value  $4.5$  to  $11.0 \times 10^3/\mu\text{L}$ ). She was given intravenous fluid resuscitation, anti-tetanus injection, intravenous broad-spectrum antibiotic, and pain reliever medications.

A noncontrast computed tomography (CT) scan (Fig. 2) and a three-dimensional CT (3D CT) of her abdominal was per-

formed and showed an iron penetrating the inguinal region and the right pelvis (Figs. 3 and 4).

Emergency laparotomy was then performed with the help of digestive surgeon, vascular surgeon, gynecologist, and orthopedist. There was through end through perforation in the terminal ileum and distal sigmoid colon so we decided to perform anastomoses resection of the sigmoid colon and end ileostomy. There were also type IIIA open fracture of left superior pubic ramus and Dennis type 3 sacral fracture found. Then debridement and sequestrectomy of the sacrum were performed. A partial rupture of the left internal iliac artery was found and vascular exploration was performed. Moreover, we found lacerations in uterine fundus, fallopian tube and left ovary therefore we repaired using continuous suturing. After digestive, vascular, gynecologist, and orthopedist surgery were done, we then started to identify urology injury. On examination, the bladder was examined by inserting 200 cc of aquadest through a urinary catheter. As a result, no leakage was found on the bladder. Our further examination revealed that no abnormalities were found on the right ureter however the left ureter was identified as having incomplete rupture in the distal 3rd of ureter. An ureteral stent then was inserted using a hydrophilic coating implant (serial number: BT-DJ-50ML 210). End to end anastomosis was performed by using vicryl 4.0. The postoperative course was uneventful, and the patient was discharged on postoperative day 30.

### Discussion

Ureteral injury occurs in less than 1% of all urological injuries [2,4]. This is explained because the ureters are well protected in the retroperitoneum by the pelvis, psoas muscles, and vertebrae [2]. Untreated ureteral injury can result significant morbidity. In addition, given the anatomical nature of the well-protected ureter, injury to this structure is often associated with significant extensive trauma and requires immediate patient management [1].

In this case, our patient is a 37-year-old woman who suffered penetrating trauma due to stove explosion during cooking. Due to this penetrating trauma, our patient was found to have ruptured in the distal 3rd ureter. This patient was immediately treated in the form of emergency surgery.

Patients with ureteral injuries often have other major intra-abdominal injuries. Several associated traumas can contribute to delays in the diagnosis and management of ureteral injuries. Symptoms of ureteral injury may include hematuria and hypotension, but these symptoms are rare. In a case series, macro-hematuria was found in only 43% of cases of ureteral injury. Usually, there are no classic signs or symptoms for ureteral injury. A clinician needs to have a high suspicion of ureteral injury in a patient with penetrating abdominal trauma [2]. In this case, our patient had several other traumas including an open fracture of the left upper pubic ramus grade 3A and open fracture of sacral dennis zone 3 grade 3A. The patient did not have hematuria, but was hypotensive. Our patient's chief complaint was persistent pain in the lower left abdomen. The patient also does not feel any sensation in her bladder and bowel movements. Given this patient had pene-

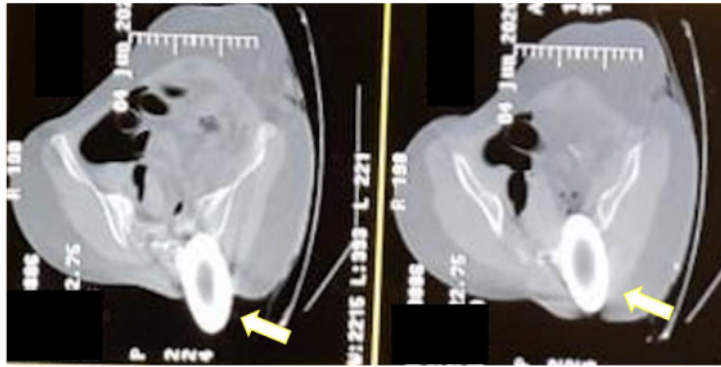


Fig. 2 – A noncontrast CT scan shows an iron object (arrow) penetrated the right pelvic (axial view).

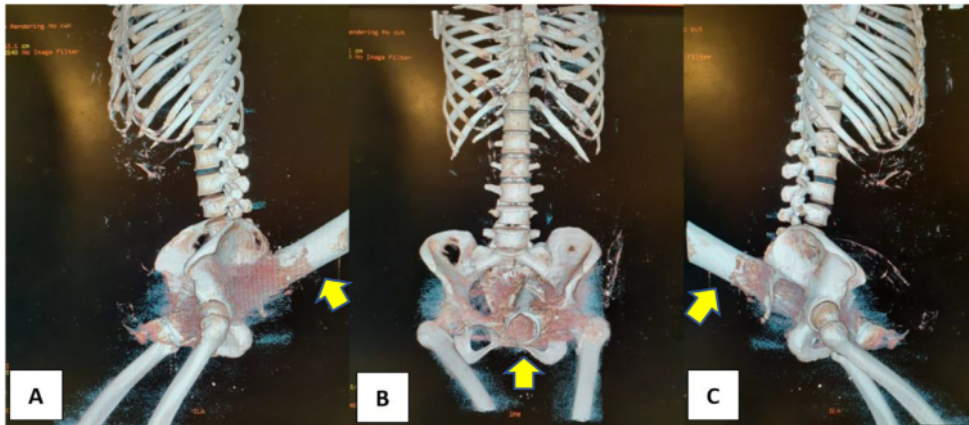


Fig. 3 – Abdominal 3D CT-scan of the lower abdomen and pelvic shows an iron object (arrow) penetrated the inguinal region and the right pelvic.

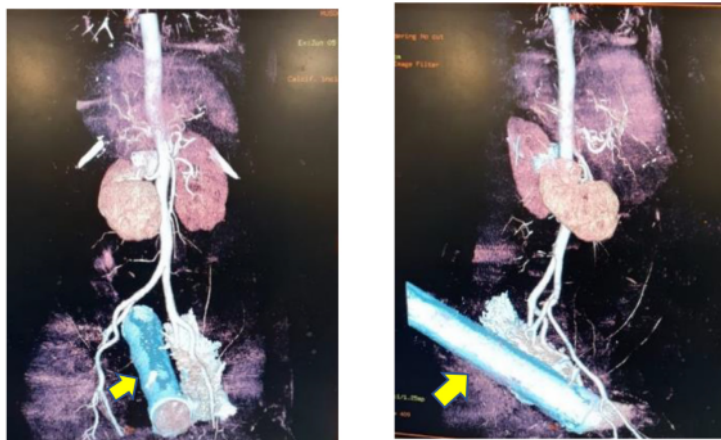


Fig. 4 – Abdominal 3D CT-scan shows the structure that is passed by the iron (arrow).

trating trauma, as a clinician we have to suspect injury to the ureter and bladder.

Computed tomography urogram examination can be performed quickly and can provide detailed anatomical information in trauma cases [4,5]. The AUA trauma guidelines recommend performing abdominal/pelvic CT with intravenous contrast and *delayed scans* (urogram) in all stable patients if ureteral trauma is suspected [5]. CT radiographic findings suggestive of ureteral injury include contrast extravasation, delayed pyelogram, hydronephrosis and lack of contrast in the urinary tract distal to the injured structure [1]. In this patient, we performed an abdominal MSCT scan. Through these examinations we found the exact location and anatomical structures involved.

The main goal of ureteral repair is to maintain renal drainage. Management options depend on the site of injury, the extent of ureteral damage, and other associated trauma. Basic surgical principles include *tension-free anastomosis*, debridement of necrotic tissue, spatulation of each ureteral end, and *water-tight anastomosis*. Suturing usually uses absorbable sutures (5-0 PDS). The use of ureteral stents has been shown to facilitate healing. The use of stents can provide canalization and may reduce the risk of strictures [1,2].

---

## Conclusion

Ureteral avulsion caused by through and through penetrating injury of pelvis was managed with a ureteral stent and end-to-end anastomosis. A multidisciplinary approach

was performed to treat other structural damages including gastrointestinal damage, pelvic bones fractures and other internal organ damages.

---

## Patient consent

Written informed consent for publication of their clinical details and/or clinical images was obtained from the patients.

---

## REFERENCES

- [1] Zaid UB, Bayne DB, Harris CR, Alwaal A, McAninch JW, Breyer BN. Penetrating trauma to the ureter, bladder, and urethra. *Curr Trauma Rep* 2015;1:119–24. doi:10.1007/s40719-015-0015-x.
- [2] Serafetinidis Kitrey ND, Djakovic N, Kuehhas FE, Lumen N, Sharma DM, et al. EAU Guidelines on Urological Trauma 2018 *Eur. Assoc. Urol. Guidel. 2018 Ed., vol. presented, Amhem, The Netherlands European Association Urology Guidelines Office; 2018.*
- [3] Nugroho EA, Wibowo DK, Wijaya YH, Korwa IY. Distal ureteric rupture caused by blunt abdominal trauma: a rare case report. *Urol Case Rep* 2019;27:100917. doi:10.1016/j.eucr.2019.100917.
- [4] Ledderose S, Beck V, Chaloupka M, Kretschmer A, Strittmatter F, Tritschler S. Management von Harnleiterverletzungen. *Urologe* 2019;58:197–206. doi:10.1007/s00120-019-0864-y.
- [5] Morey AF, Brandes S, Dugi DD, Armstrong JH, Breyer BN, Broghammer JA, et al. Urotrauma: AUA guideline. *J Urol* 2014;192:327–35. doi:10.1016/j.juro.2014.05.004.

# Ureteral avulsion caused by through and through turniti

## ORIGINALITY REPORT

3%

SIMILARITY INDEX

2%

INTERNET SOURCES

2%

PUBLICATIONS

0%

STUDENT PAPERS

## PRIMARY SOURCES

1

[docplayer.net](#)

Internet Source

1%

2

Harry Wahyudhy Utama, Anita Widyoningroem. "Corrigendum to "Situs inversus with congenital absence of left circumflex artery and a superdominant left-sided right coronary artery: A case report" [Radiology Case Reports 17 (2022) 735-739]", Radiology Case Reports, 2022

Publication

1%

3

[s3.amazonaws.com](#)

Internet Source

1%

Exclude quotes On

Exclude matches Off

Exclude bibliography On